UROLOGIC IMAGING:

The Past, The Present and The Future

BRUCE R. GILBERT. M.D., PH.D.
NATIONAL UROLOGIC ULTRASOUND FACULTY
AMERICAN UROLOGICAL ASSOCIATION

ASSOCIATE CLINICAL PROFESSOR OF UROLOGY AND REPORDUCTIVE MEDICINE
WEILL CORNELL MEDICAL COLLEGE

DIRECTOR, REPRODUCTIVE AND SEXUAL MEDICINE
THE SMITH INSTITUTE FOR UROLOGY
NORTH SHORE LIJ HEALTH SYSTEM

In the Beginning…

- Introduction of X-rays by German professor Wilhelm Conrad Röntgen on Nov. 8, 1895.
  - Nobel prize for physics 1901
- Scottish otolaryngologist, John Macintyre made the first radiograph of a kidney stone in a patient on April 2, 1896

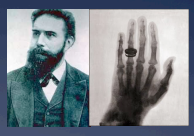

Retrograde Pyleography

- Röntgen demonstrated that dark and light areas on photographic film were caused by differential absorption of rays passing through tissues of various densities.
  - Contrast was thus needed to distinguish kidneys, ureters or bladder.
- 1906, when German surgeons Alexander von Lichtenberg and Fritz Voelcker used a silver solution (Collargol) through the bladder up into the kidneys 'lighting up' previously 'dark' areas of the urinary tract

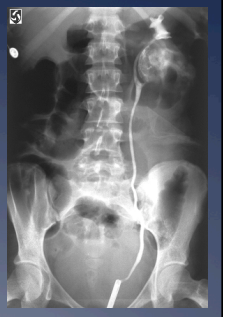

Intravenous Pyelogram

- 1929 by American urologist Moses Swick Working with von Lichtenberg in Berlin, injected an organically bound iodine solution (Uroselectan) into a vein while taking pictures.

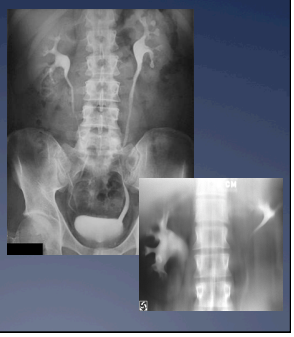

Competing technologies….

- X-Ray (Planer and CT)
- Magnetic Resonance Imaging (MRI)
- Nuclear Imaging (Gamma Ray, SPECT, PET)
- Ultrasound
- Other (Infrared, Microwave, Nanotechnology…)

Electromagnetic Spectrum

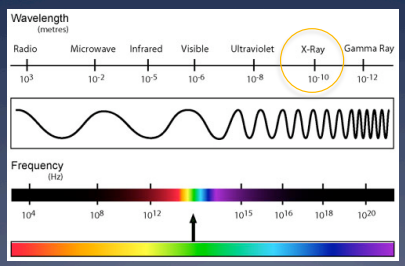

Planer X-Ray Imaging

- Planar-projection
  - Standard radiography (Film, digital, fluroscopy)
  - Digital Subtraction
  - Digital Tomosynthesis
  - Fast digital technology
    - Scanning speed, improved resolution, 3D reconstruction
- Tomographic approaches
  - CT: axial-mode non-helical, helical (spiral) CT

Planar Projection

IVP (c1929)

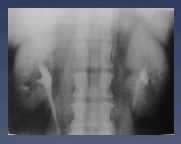

Tomography

Digital Subtraction

Tomographic Approaches

Digital Tomosynthesis

- Multiple planer images generated at arbitrary depths
- A series of discrete projection radiographs are digitally acquired
- Through digital manipulation the "blur" is subtracted
- Section thickness can range from 1 mm to several cm

CT scanning

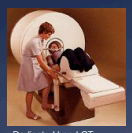

Dedicated head CT scanner, circa 1974

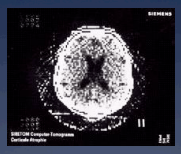

Multiuse 64 slice CT scanner, circa 2009

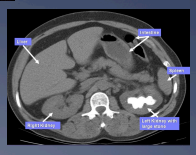

Tomographic Approaches

- Axial-mode non-helical CT
- Helical (spiral) CT
  - Table and X-ray tube move continuously
    - 3rd generation if rotating array of detectors
    - 4th generation if thousand or more detectors surround the patient fixed in space
      - Avoids ring artifact seen with 3rd generation
    - 5th generation or electron beam CT is fast but tends to produce "noisy" images and is presently reserved for calcium scoring.
- Single to multi-section imaging
  - Image acquisition up to 64 sections of the body simultaneously
    - Faster image acquisition times
      - 0.33 sec rotation time
    - Improved 3D image quality with rapid coronal and sagittal reconstitution possible
      - 0.4 mm spatial resolution

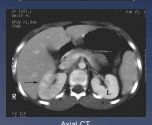

Axial CT

Helical CT with Coronal reconstruction

CT Scanning "Wish list"

- Greater scanning speed
  - Gantry rotation is limiting factor due to centrifugal forces
  - Greater longitudinal (z-axis) anatomic coverage
- Greater image resolution
  - Improved detector systems
  - With multisection imaging comes an increase in Compton scatter radiation reaching the image receptors resulting in a decrease resolution of the image.
- Decreased radiation
  - It is estimated that, per year, diagnostic x-ray use in the United States causes 0.9% of the cumulative risk of cancer to age 75 in men and women, equivalent to 5695 cases. de Gonzalez AB, Darby S, Lancet. 2004;363:345-351.
  - The US Food and Drug Administration (FDA) estimates that a CT examination with an effective dose of 10 millisieverts (mSv)…1 CT examination of the abdomen… may be associated with an increase in the possibility of fatal cancer of approximately 1 chance in 2000 http://www.fda.gov/cdrh/ct/risk.html
- Biomedical Informatics
  - Storing, displaying and interpreting the vast amount of data and images in a diagnostically useful way

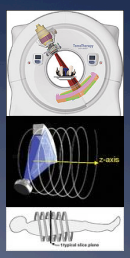

Nuclear Imaging

- Gamma Ray
  - Images produced by a pharmaceutical and a gamma counter (technitium 99m)
- SPECT (Single photon emission computed tomography)
  - Gamma ray counterpart of CT
- PET (Positron emission tomography)
  - Makes use of positron emitters ^{15}O, ^{13}N, ^{11}C, ^{82}R, ^{18}F
  - Detection, localization, staging and monitoring of tumors
- PET/CT, SPECT/CT (also PET/MR, SPECT/MR)
  - Projection of a visual physiologic image onto detailed anatomic map

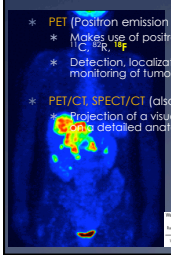

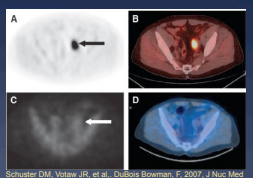

Schuster DM, Votaw JR, et al., DuBois Bowman, F, 2007, J Nuc Med

TOP IMAGE: PET/CT Prostate Imaging
67 yo male with increased uptake of Anti-F-18-FACBC (synthetic amino-acid analog whose uptake by prostate carcinoma cells is likely mediated via the sodium-independent L large-neutral amino acid transport system.

BOTTOM IMAGE: SPECT/CT
Axial Spect/CT with ^{111}In-capromab pendetide (ProstaScint®) show no significant activity in that region.

Magnetic Resonance Imaging

- MR imaging (T2WI) interrogates the water-biological molecule interaction reveling information about the anatomy and physiologic status of the tissue.
  - Advantages: No ionizing radiation
  - Disadvantages: Long acquisition time
- MR Angiography: generates images of the arteries
- Diffusion MR Imaging (DWI): reveals information about the direction of blood diffusion
- Contrast Enhanced Image (CEI): Contrast agents by shortening the T1 or T2 relaxation time of protons located nearby. Reduction of T1 relaxation time results in a hypersignal while reduced T2 relaxation time reduces both T2 and T2 signals.
- MR Spectroscopy and Chemical Shift MR:
  - Can identify chemical processes in small volumes
  - Can be combined with high resolution MR imaging to enhance sensitivity and specificity in tumor detection
- Functional MR imaging : Blood oxygen-dependent imaging
- Zero quantum imaging: uses the image interference of the magnetic coupling between nuclear spins that are even millimeters apart to gain additional information about the tissue.

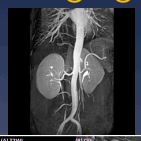

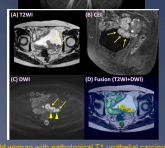

A 70-year-old woman with pathological T1 urothelial carcinoma
(A) Transverse T2WI shows a papillary tumor (arrow
(B) Sagittal dynamic CEI shows enhanced and structures (arrow) consisting of tumors and submucosa.
(C) Transverse DWI depicts the tumor (arrow) and submucosal stalk (arrow head) separately.
(D) Fusion of transverse T2WI with color-encoded DWI
M Takeuchi, UroToday, 11/2009

Ultrasound

- High frequency sound echos are produced at boundaries between tissues of differing elastic properties or densities
  - 2-15 MHz range Standard
  - 10-40 MHz for vascular imaging….to several 100 MHz
- Advantages
  - No exposure to ionizing radiation
  - No age or size limitations: fetus to elderly
- Tremendous advancements over the years
  - Decreased size of transducers and equipment
  - Contrast agents
  - Hardware and software developments

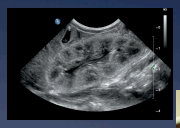

ULTRASOUND

- 2D Imaging
  - B-Mode
  - Color Doppler
  - Power Doppler
- 3D imaging
  - multiple planes
- 4D imaging
  - multiple planes with rapid rendering

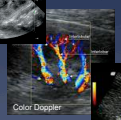

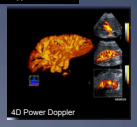

Ultrasound Enhancements

- Contrast Agents
  - Ultrasound contrast agents are gas-filled microbubbles that are administered intravenously to the systemic circulation.
- Harmonics
  - Harmonics are additional frequencies that are multiples of the fundamental (transmitted) frequency.
  - Transmit at 5 MHz and receive at 10 MHz
  - Significant improvement in resolution.
  - Tissue harmonic imaging

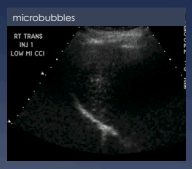

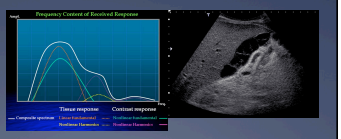

Ultrasound Enhancements

- Elastography
  - 2D correlation in both axial and lateral directions
  - Relative tissue elasticity is calculated and displayed as a color overlay on the conventional B-mode image.
  - Stiffer tissue structures are displayed in blue, while the more easily deformed tissues are in red
- HistoScanning™
  - tissue differentiation, visualization and quantification by extracting information from 3-D ultrasound data

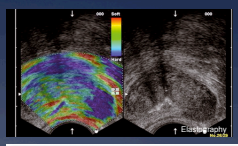

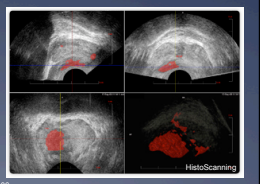

1. Govindaraju S, et al. British Journal of Medical and Surgical Urology (2008) 1, 98-106
2. Braeckman J, et al. BJU Int. December 2008;102(11):1560-1565. E-pub 2008 Aug 14.
3. Braeckman J , et al. BJU International. Feb 2008;101(3):293-8.

Developing and Evolving Technologies

- Diaphanography (transillumination)
- Terhertz Imaging
- Microwave imaging
- Thermography
- Tissue Electric Impedance Tomography
- Cellular and Molecular Imaging
- Mini and Nanotechnology
- Computers: PACS, DICOM, Computer aided Detection….and more

Diaphanography

- Transillumination with either an intense laser beam or with a near-infrared light source (700 -900 nm) and a camera sensitive to this wavelength.
- Oxygenated and deoxygenated blood absorb these wavelengths well but have spectra that differ enough to allow distinction between the two.
- Safe and cost effective
- Presently used in breast
  - Potential urologic applications include scrotum and prostate

Breast with tumor. Increased light absorption by tumor associated angiogenesis

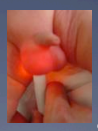

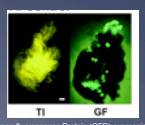

Green fluorescence Protein (GFP) expression in the prostate of Human Prostate Stem Cell Antigen (PSCA)-GFP transgenic mice.
TI = Transillumination
GF = Green fluorescence

Terhertz Imaging

- Terahertz portion (T waves) between 300 and 100 um wavelength.
- Do not penetrate water or tissue well but ideal for epithelium
  - Non-ionizing, portable equipment
  - Can recognize spectral fingerprints of surface proteins…even those not visible
  - Can locate tumors and other superficial lesions at an early stage
- Used for Airport Security
- Potential Urologic uses include:
  - Penile cancer
  - Condylomata





In Vivo terahertz imaging of forearm with handheld device

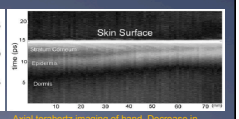

Axial terahertz imaging of hand. Decrease in stratum corneum thickness from palm side to backside of hand

Microwave imaging

- Microwaves are particularly sensitive to differences in tissue absorption
- However, the relatively long wavelength of microwaves results in low resolution images
- Electron-Spin resonance imaging (aka electron paramagnetic resonance imaging or EPR) is similar to MR but involves spin transitions of unpaired electrons instead of protons
  - Since an electron is lighter, the electrons MR is 28 GHz instead of 42 mHz for a proton which results in absorption of the microwaves in a millimeter of skin. Using lower resonant frequencies and field strengths (0.01-0.04 T) allows imaging of free radicals in vivo without tissue heating.
- Proton-Electron double-resonance imaging (PEDRI) is simultaneous electron-spin resonance and nuclear MR imaging

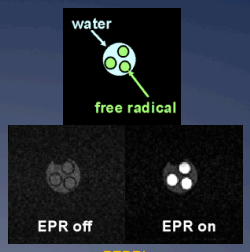

PEDRI

Thermography

- Unlike the other imaging modalities, Thermography involves extraction of information from the electromagnetic radiation produced by the body.
- Thermography can play a role in locating high undescended testes which are nonpalpable and not detected by ultrasonography. Lai et al, *Eur Urol* 1998;33:209-213
- Also used in varicocele detection and follow up with ultrasonography.

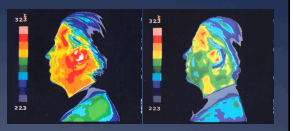

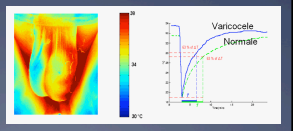

Tissue Electric Impedance Tomography

- A Tissue's electrical impedance (TEI) is the resistance of tissue to the movement of electrons.
- By applying a low voltage between a pair of skin electrodes and measuring current the tissue impedance is measured (Z =V/I)
- Like MR, The TEI is sensitive to changes in tissue water content
- Present applications include blood loss, gastric emptying, pulmonary ventilation and tumor assessment
  - Advantages: safe, portable device, long term data acquisition possible, low cost
  - Disadvantage: number of electrodes that can be placed, electric currents do not follow a straight line.
- Applications for Urology might include nom-invasive, safe and low cost follow up of Renal and Prostate cancers.

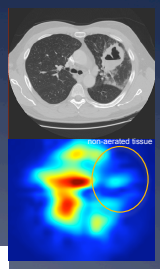

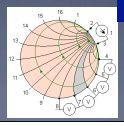

Cellular and Molecular Imaging

- Minimally invasive in vivo sensing of biological processes at the cellular and molecular level
- The development of novel molecular agents that attach with his specificity to genes, proteins or other biomolecular targets can be detected by various imaging modalities
- The development of micro-CT, micro-MR, micro-PET, optical bioluminescence, fluorescence molecular tomography equipment is quickly advancing the field of Molecular imaging and Biophotonics

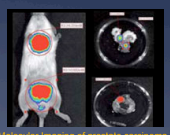

Molecular Imaging of prostate carcinoma with lung metastases in vivo and ex vivo.

Nanotechnology

- Nanoparticles that display specific physical or chemical characteristics for example Quantum dots
- Quantum dots
  - made from semiconductor crystals of cadmium selenide encased in a zinc sulfide shell as small as 1 nanometer (billionth of a meter). The quantum dots can be sealed in a polymer capsule to protect the body from exposure to the cadmium
  - In ultraviolet light, each dot radiates a brilliant color.
  - Attached to the surface of each capsule are monoclonal antibodies directed against prostate-specific surface antigen

Computer and Software Technology

- PACS (picture archiving and communication systems)
  - Ideally integrated with radiology and hospital information systems.
  - Remote and web-based options
  - Standardization of PACS-machine connectivity and simpler user interfaces will make PACS indispensible for high-quality and cost-effective healthcare.
- DIACOM (Digital Imaging and Communications in Medicine)
  - Standard for handling, storing, printing, and transmitting information in medical imaging.
  - Enables the integration of scanners, servers, workstations, printers, and network hardware from multiple manufacturers into a PACS.
- Pattern recognition and Computer aided detection
  - Computed Assisted Detection of Lymph Node Metastasis or Prostate Cancer from high resolution MR images
  - Detection of prostate cancer from digitized histology

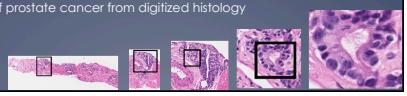

Conclusions

- Imaging in Urology continues to rapidly advance.
- A need is for imaging modalities that do not use ionizing radiation.
- Portable imaging units will reduce costs and make imaging more available.
- Spectacular developments in Nanotechnology will provide both a diagnostic and therapeutic modality at the same time.
- Advances in PACS and CAD will allow for rapid and improved detection of urologic pathology.

Obrigado!

www.BruceGilbertMD.com